

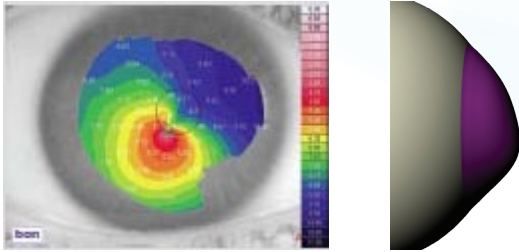
Fitting Manual Example: DECENTERED CONE

Standard Periphery (STD)

History

Patient has been a GP wearer since being diagnosed with keratoconus 14 years previously (VA this eye 20/40). The cornea had central scarring and significant staining with fluorescein. The patient was advised to discontinue the lens until refitting due to lens intolerance and corneal staining.

Identifying Corneal Shape



Decentered/Low Keratoconus Moderate

In this case, the spectacle refraction has been affected by central scarring

Spectacle Rx:	+1.25 -6.25 x 50 VA 20/50
Sim Ks (D):	6.13mm x 5.39mm (55.00D x 66.62D)
Steepest curvature:	4.75mm (71.00D)
Flattest curvature:	9.30mm (36.25D)
Curvature of 'green area':	7.50mm (45.00mm)
Corneal Astigmatism:	-7.58D x 11 @ 3mm -6.56D x 41 @ 5mm

The normal relationship between refraction and corneal shape has changed due to central scarring. Decentered cones often demonstrate oblique axes, which can be a useful clue if topography is not available. This cornea demonstrates a very flat periphery on topography but this may not, in fact, mean the corneo-scleral junction is flat.

Conclusion: This corneal shape is consistent with moderate decentered/low keratoconus.

Initial Lens Choice

For moderate decentered cones, the suggested choice is 8.40mm base curve/STD.

MoRoCCo VA findings for 8.40mm base curve/STD

Lens assessed within the first 5 minutes

Movement:	3.0mm post blink
Rotation:	15° counter-clockwise
Centration:	Lens was decentered 2.0mm nasally, dropping to limbus on upward gaze
Comfort:	Some edge awareness
VA:	Over-refraction: +1.00 -6.00 x 60 VA 20/40 with ghosting, visual acuity becoming worse after blink

Conclusion: Flat-fitting lens

Action: A retrieval with 8.20mm base curve/STD lens

Fitting Manual Example: DECENTERED CONE

Initial Lens Choice (continued)

MoRoCCo VA findings for 8.20mm base curve/STD Lens assessed within the first 5 minutes

- Movement:** 3.00mm post blink
- Rotation:** 5° counter-clockwise, unstable rotation, especially on upward gaze
- Centration:** Lens was decentered 0.5mm nasally, dropping to limbus on upward gaze
- Comfort:** Comfortable
- VA:** +1.00 -6.00 x 60 VA 20/30+ and still slightly worse after the blink

Conclusion: Lens still slightly flat

Action: Retrial with 8.00mm base curve/STD

MoRoCCo VA findings for 8.00mm base curve/STD Lens assessed within the first 5 minutes

- Movement:** 1.0mm-2.0mm post blink
- Rotation:** Stable at vertical position
- Centration:** Centered
- Comfort:** Comfortable
- VA:** With same over-refraction, VA was 20/25+, stable before and after the blink

Conclusion: Lens had all parameters in (optimal range) from Fit Assessment Chart

Action: Lens was optimal and ordered

Discussion Points:

- The flattest and steepest areas on topography can be misleading. Therefore, evaluate the corneal profile and start fitting with STD lenses from the diagnostic fitting set rather than order flatter fitting lenses
- Keep in mind the lens is fitting the whole cornea, not just the steepest area. In this case, it might have been tempting to go straight to the 7.80mm base curve.

If this had been done, the following MoRoCCo VA characteristics would have been found:

- Movement:** 1.0mm post blink
- Rotation:** Stable at vertical position
- Centration:** Centered with no drop on upward gaze
- Comfort:** Comfortable
- VA:** 20/30 and slightly clearer after the blink

If this had been the only lens tried, the patient may have missed the opportunity to achieve better visual acuity with the 8.00mm base curve/STD lens.